



Clinical application of a specialized hand held pedicle drilling tool for pedicle screw placement in thoraco-lumbar fusions



Victor Chang M.D., Sanjay Patra M.D., Mokbel Chedid M.D.,
Henry Ford Health System, Detroit, Michigan

Abstract

Introduction: Despite the use of fluoroscopy and other image guidance systems, pedicle breaches are not always detected at the time of surgery and can result in injury. In addition, routine use of fluoroscopy exposes both the patient as well as surgical team to radiation. The use of a specialized hand held pedicle drilling tool has been described to minimize these risks.

Methods: A retrospective review of 60 adult patients where the device was used primarily for pedicle screw placement. 42 patients underwent computed post-operatively to evaluate for the presence of screw breach of the pedicle wall.

Results: Out of a total of 268 screws placed 3 were found to breach the medial pedicle wall, with no lateral, superior or inferior wall breaches. This amounts to a 98.9% accuracy rate in the placement of pedicle screws with the assistance of this device. None of the patients required re-operation for replacement of screws, and none had any symptomatic neurological sequelae as a result of pedicle wall breach.

Discussion: An accuracy rate of 98.9% is consistent with previous clinical studies which have shown that this device has a 98% sensitivity and 99% specificity for detecting pedicle breaches. In comparison to a large meta-analysis of pedicle screw placement accuracy there is a 3.7% absolute reduction or a 22.9% relative reduction of the probability of misplaced pedicle screws. Coupled with free hand techniques which can achieve 94.2% accuracy in some studies this device can increase accuracy as well as reduce the amount of radiation exposure required for this procedure.

Conclusion: The use of this tool can be a helpful adjunct to traditional techniques for the placement of thoracolumbar pedicle screws. The feedback from the tool can be useful in increasing the accuracy of pedicle screw placement.

Introduction

- The application of instrumented fixation for thoracolumbar arthrodesis has led to the near ubiquitous use of pedicle screw-rod systems
- Despite the use of fluoroscopy and other image guidance systems these measures do not guarantee detection of a pedicle breach intra-operatively
- Pedicle breach can result in nerve root injury, durotomies with subsequent CSF leaks which may result in re-operation with an increased risk of morbidity
- Routine use of fluoroscopy subjects both the patient as well as operating room staff to radiation
- We report our experience with a hand held pedicle drilling tool for pedicle screw placement in thoracolumbar fusions.

The Device

- PediGuard™ by SpineVision
- Device provides auditory feedback every 0.5 seconds both through impedance variation and evoked muscle contractions
- The tool is shaped like an awl and is meant to be used in place of a regular awl, this results in a shallow learning technical learning curve when integrating the device into one's usual practice

Methods

- Reviewed 60 adult patients where the device was used primarily for preparation of pedicle screw placement for instrumented arthrodesis in the thoraco-lumbar spine
- 42 patients evaluated with computed tomography (CT) scanning post-operatively to assess for pedicle breach

Description of Technique

- Identification of start point anatomically as the intersection a vertical line along the lateral pars boundary and a transverse line dividing the transverse process in half
- A drill is used to perforate the cortex at the starting point
- The device is slowly advanced to cannulate the pedicle and body. If the device indicates a breach has occurred it is withdrawn and a new trajectory is attempted.
- A ball-tipped probed is used to palpate the walls of the tract to confirm the presence of circumferential bone
- Titanium screws were used depending on the size of the pedicle as determined by a preoperative CT scan.

Results

- 60 total patients reviewed, 42 evaluated with CT scan
- 2 thoracic screws placed, 202 lumbar screws placed, 64 sacral screws placed and evaluated with CT
- Overall number of pedicle breaches noted on post-operative imaging were 2 lumbar and 1 sacral. All 3 breaches were medial
- 1.1% pedicle breach when using this device, or 98.9% accuracy rate
- None of the breaches were clinically significant and without the need for re-operation

Illustration of Pedicle Breaches

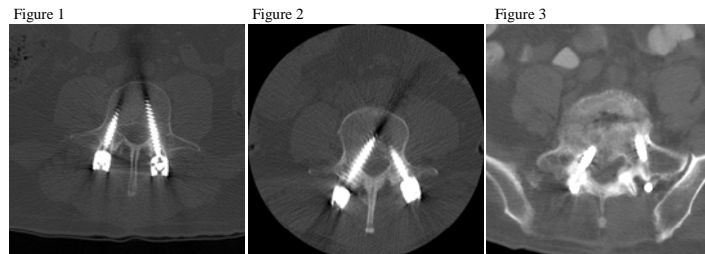


Figure 1: Medial penetration on the left L4 screw Figure 2: Medial penetration on the right L4 screw Figure 3: Medial penetration on the right S1 screw

Tables

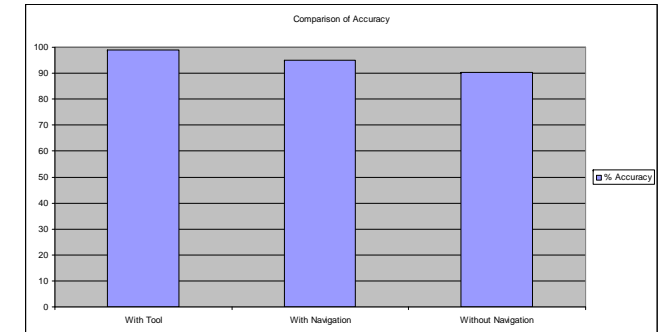


Table 1: Comparison of results from this study versus those published by Kosmopoulos et al (4).

Discussion

- Previous studies have shown that the instrument has a 100% specificity and 97% sensitivity in detecting pedicle wall breaches in a porcine model (1), and a 98% sensitivity and 99% specificity during clinical trial (2). An accuracy rate of 98.9% in actual clinical practice seems consistent with this previous observation
- A large meta-analysis of the literature revealed a 90.3% accuracy in screws placed without navigational guidance, and 95.2% (4) accuracy in those placed with some sort of navigational guidance
- The observations of this study show a 3.7% absolute reduction or a 22.9% relative reduction of pedicle breaches when compared to other forms of navigational guidance
- Other free hand techniques have been shown to have up to 94.2% accuracy, this technique has the advantage of not using intra-operative fluoroscopy (3)
- This tool can be a useful adjunct in free hand techniques with increased accuracy

References

1. Bolger C., Carozzo C., Roger T., McEvoy L., Nagaria J et al. A preliminary study of reliability of impedance measurement to detect iatrogenic initial pedicle perforation (in the porcine model). Eur Spine J (2006) 15: 316-320
2. Bolger C., Kelleher M., McEvoy., Brayda-Bruno M., Kaelin A et al. Electrical conductivity measurement: a new technique to detect iatrogenic initial pedicle perforation. Eur Spine J (2007) 16:1919-1924
3. Karapinar L., Erel N., Ozturk H., Altay T., Kaya A. Pedicle screw placement with a free hand technique in thoracolumbar spine: Is it safe?. J Spinal Disord Tech (2008) 21:63-67
4. Kosmopoulos V., Constantin S. Pedicle Screw Placement Accuracy. Spine (2007) 32:E111-120.